


Flatfoot Reconstruction

A case study featuring the Cotton procedure utilizing the Vitrium® Wedge
vs an Evans procedure with allograft

16 WEEK RESULT



Vitrium C Wedge

[▶ Click here](#)




i2b IS A GLOBAL EXTREMITY COMPANY

6060 Poplar Dr., Suite 380, Memphis, TN 38119
844. 602. 6637 or visit i2b-USA.com

Flatfoot Reconstruction

A case study featuring the Cotton procedure utilizing the Vitrium Wedge vs an Evans procedure with allograft



16 WEEK RESULT

INTRODUCTION:


Classic Flatfoot deformity presents a wide variety of foot disorders that include hindfoot valgus, forefoot varus and forefoot abduction. In this case, a 59 year old male is presented with 2b Adult flatfoot deformity. The patient's posterior tibial tendon is intact, but the Spring ligament is torn (Figure 1).

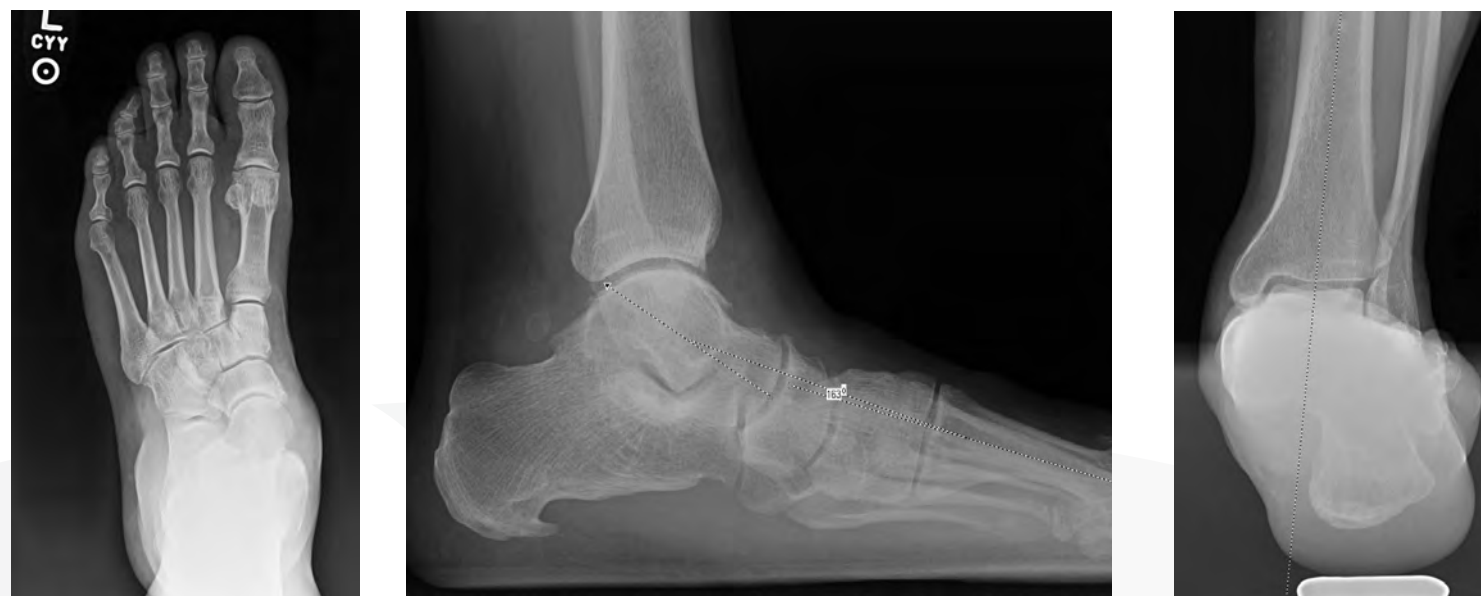

Figure 1: 59 year old male with 2b Adult flatfoot deformity

Flatfoot Reconstruction

A case study featuring the Cotton procedure utilizing the Vitrium Wedge vs an Evans procedure with allograft



16 WEEK RESULT


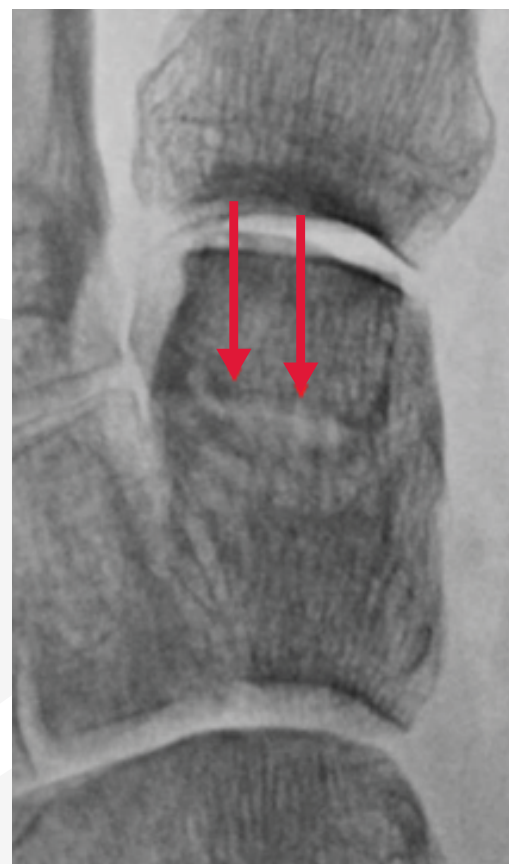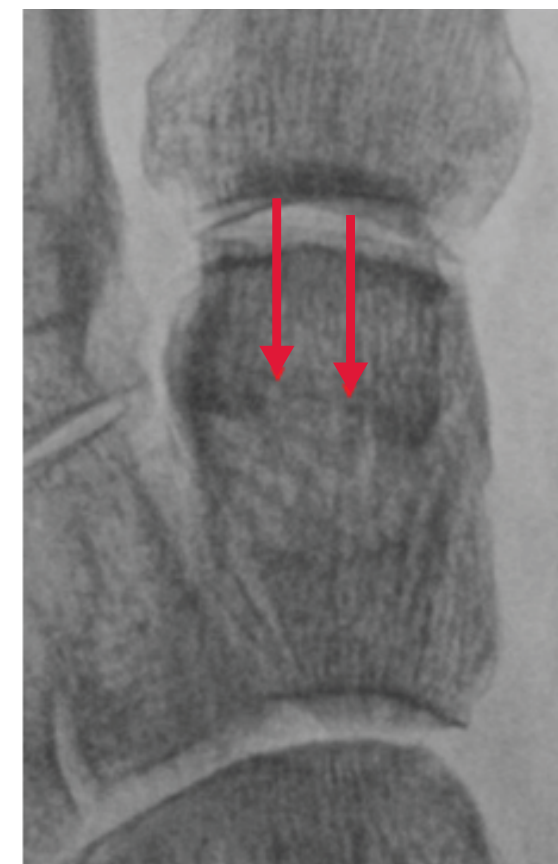Cotton procedure: The surgical treatment involved ligament repair, a Cotton procedure (Figure 2) with the Vitrium[®] wedge (a Bioactive Glass resorbable implant) and an Evans procedure with an allograft. The purpose of this case study is to report on the performance of the Vitrium Wedge as an effective replacement for allograft in opening wedge procedures. In this particular case, the Vitrium wedge was used as a plantar flexion opening wedge of the medial cuneiform (Cotton) osteotomy versus an allograft for the Evans procedure. 

Figure 2: Cotton procedure with Vitrium - Vitrium is replaced by native living bone with new bone remodeling & normal trabecularization.




11 weeks



16 weeks

Flatfoot Reconstruction

A case study featuring the Cotton procedure utilizing the Vitrium Wedge vs an Evans procedure with allograft



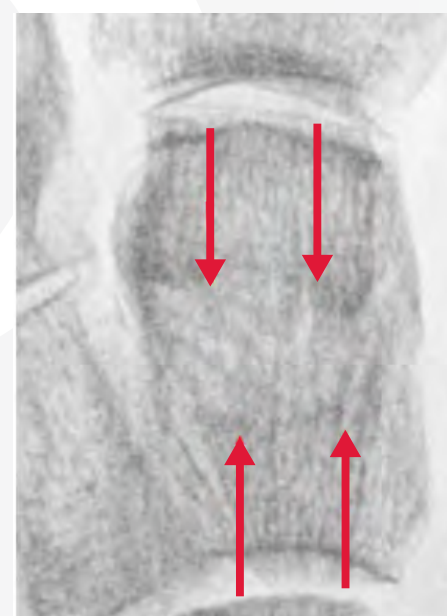16 WEEK RESULT

CONCLUSION:

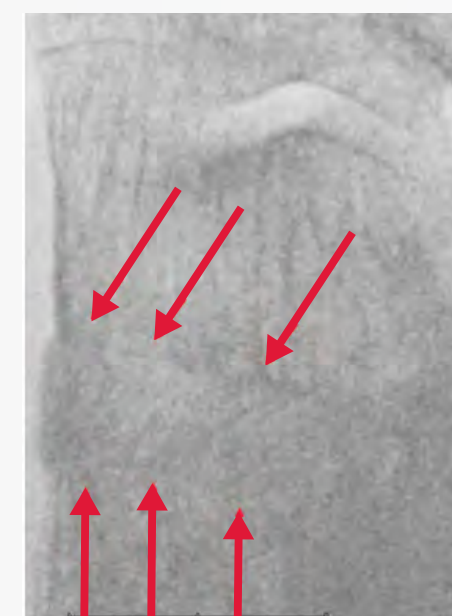The Cotton procedure (opening wedge cuneiform osteotomy) is a commonly used treatment to correct the flatfoot varus component of flatfoot deformity. In this case, the Vitrium Wedge was used as a replacement for allograft and an allograft was used for the Evans procedure. The x-ray analysis clearly shows the patients host bone substituting the Vitrium Wedge over the course of 16 weeks versus the performance of the Evans allograft where the host bone at 16 weeks is growing to the edge of the allograft (Figure 3), but not incorporating throughout the allograft. Given the difficulties of cost, sizing, quality and availability associated with allograft material, the Vitrium Wedge is an effective

alternative to allograft and may present a more efficient model for bone remodeling and incorporation.

Figure 3: Cotton with Vitrium [left] and Evans with allograft (right). Red arrows show the host bone in the Cotton substituting with Vitrium vs. the Evans where bone is growing to the edge without incorporating the allograft.



16 week Cotton



16 week Evans